



JSMCR-25-31

## Managing of Rhinoscleroma in Children: Medical vs. Surgical Treatment-What is the Optimal Approach? A Case Report

Laghsene Loubna\*, Rsaissi Chaimae, Lita Zineb, Lahjaouj Meriem, Loudghiri Meryem, Bijou Walid, Oukessou Youssef, Rouadi Sami, Abada Reda, Roubal Mohammed and Mahtar Mohammed

Department of Head and Neck Surgery, Université Hassan II de Casablanca, Casablanca, Morocco

\*Corresponding author: Laghsene Loubna, Department of Head and Neck Surgery, Université Hassan II de Casablanca, Casablanca, Morocco, E-mail: loubnalarsen@gmail.com

Received date: March 03, 2025; Accepted Date: March 13, 2025; Published date: April 03, 2025

Citation: Loubna L, Chaimae R, Zineb L, Meriem L, Meryem L, et al. (2025) Managing of Rhinoscleroma in Children: Medical vs. Surgical Treatment-What is the Optimal Approach? A Case Report. J Surg Med Case Rep Vol.2 No.2: 031.

### Abstract

**Introduction:** Rhinoscleroma is a chronic infection caused by *Klebsiella rhinoscleromatis*, rare in Morocco but endemic in parts of Africa and the Americas. It is linked to poor hygiene, immunodepression, and contact with infected individuals. The disease affects the upper respiratory tract, spreading through inhalation of contaminated droplets and can cause significant nasal and respiratory obstruction.

**Case presentation:** A 10-year-old male presented with a 4-years history of nasal obstruction and purulent rhinorrhea. Clinical examination revealed a mass in the right nasal cavity, causing septal deviation and complete obstruction. CT and MRI confirmed the mass, extending to both sides without bone destruction. A biopsy was performed and revealed rhinoscleroma. The patient underwent surgical excision. The histopathological analysis confirmed the diagnosis. The clinical evolution was favorable, with complete resolution of the mass and relief of nasal obstruction, all without long term antibiotic treatment. No recurrence was observed during follow-up.

**Conclusion:** the main takeaways are that surgery alone was sufficient, with no need for postoperative long term antibiotic therapy, contrary to the literature. The patient had full recovery with no recurrence. Surgery is a viable alternative to long-term medical treatment, especially in children or when antibiotics are contraindicated.

**Keywords:** *Klebsiella rhinoscleromatis*; Respiratory tract; Patient; Medical treatment; Morocco

### Introduction

Rhinoscleroma is a chronic granulomatous infection caused by *Klebsiella rhinoscleromatis*, endemic in parts of Africa and the Americas but rare in Morocco. It primarily affects the upper respiratory tract, spreading through inhalation of contaminated droplets. The disease is linked to poor hygiene, immunodeficiency, and contact with infected individuals. Symptoms evolve from nasal discharge and crusting to epistaxis and deformities due to cartilage destruction. Diagnosis is confirmed through biopsy and imaging, and while antibiotics can manage early stages, surgery is necessary for advanced cases with airway obstruction or tissue damage.

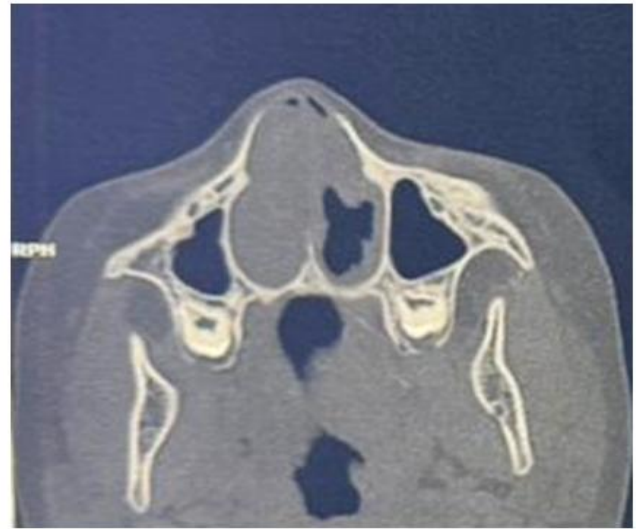
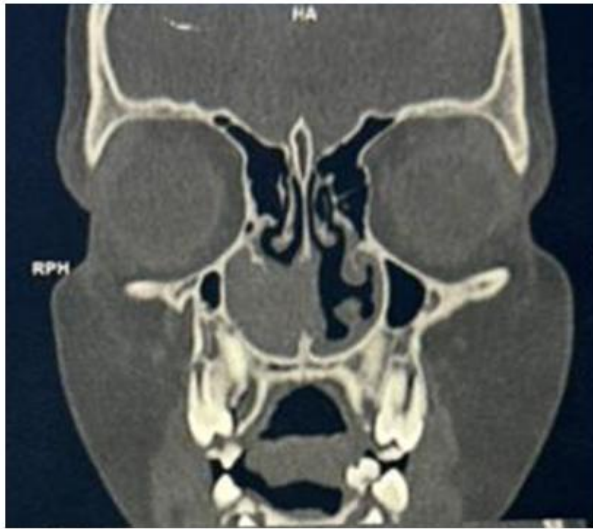### Case Report

A 10 years old male patient, with no particular pathological antecedents, was referred to our department for a bilateral nasal obstruction predominantly on the right side, evolving for 4 years (at

the age of 6 years) associated with purulent rhiorhoea but without epistaxis or anosmia or other associated signs, all evolving in a context of conservation of general condition.

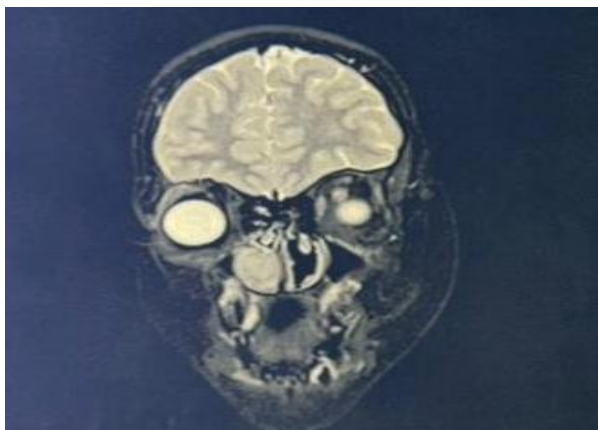
The clinical examination revealed a pinkish irregular mass completely filling the right nasal cavity and exerting a mass effect, causing a deviation of the nasal septum toward the contralateral side, which was also completely obstructed. The nasopharynx could not be visualized as the mass obstructed the passage of the endoscope. Furthermore, no cervical lymphadenopathies were found. The rest of the facial examination was unremarkable.

A facial CT scan was ordered and showed a tissue process filling the entire right nasal cavity, involving the inferior and middle turbinates, causing an obstruction of the ipsilateral nasal cavity. Extended to the contralateral nasal cavity, without any identifiable bone destruction (**Figure 1**).



**Figure 1:** Axial/coronal facial CT scan images showing the tissue process of the right nasal cavity.

The Facial MRI showed a mass in the right nasal cavity extending to the contralateral nasal cavity. Without any bone destruction or extension into the adjacent tissues (**Figure 2**).



**Figure 2:** Coronal facial MRI image showing the mass centered in the right nasal cavity.

The patient underwent a biopsy of nasal mass under local anesthesia and the histological study revealed a dense inflammatory infiltrate in the dermis, composed of plasma cells, lymphocytes, and histiocytes with abundant cytoplasm containing intracellular bacteria, in favor of rhinoscleroma, without signs of malignancy.

The patient underwent a complete excision of the mass in the right nasal cavity under general anesthesia. The surgical specimen was studied, and the definitive histopathological analysis confirmed the diagnosis of rhinoscleroma.

The clinical evolution was very favorable, with significant and clear improvement, including complete resolution of the mass and subsequent relief of the nasal obstruction, all without receiving any medical (antibiotic) treatment.

Therefore, it can be concluded that surgical treatment alone is sufficient and does not need to be combined with postoperative antibiotics (such as ciprofloxacin for 6 weeks), contrary to what is described in the literature. The patient showed excellent recovery, with no signs of recurrence during the postoperative follow-up.

Thus, surgery can be considered a viable alternative to long-term medical treatment, especially in children or when antibiotics are contraindicated. This approach helps avoid the risks associated with medical treatment, which may fail, and provides the option of proceeding with surgery as a secondary measure if necessary.

## Discussion

Rhinoscleroma is an infectious disease caused by the bacterium *Klebsiella rhinoscleromatis*, an encapsulated gram-negative member of Enterobacteriaceae that can be isolated by culture medium. It is considered endemic to some countries of Africa, Central America, and South America, but is rare in Morocco [1]. It is associated with some predisposing factors such as low socioeconomic status, poor hygiene, immunodepression, and contact with infected patients [2].

Rhinoscleroma is a chronic granulomatous disease affecting the region between the nose and the subglottis, where the germ *Klebsiella* is spread by inhalation of contaminated droplets [4].

Clinically, the symptoms depend on the stage of the disease. In the atrophic stage, patients present with fetid nasal discharge and crusting, followed by the granulomatous stage, wherein patients develop epistaxis and nasal deformity, secondary to the destruction of the nasal cartilages [4].



The differential diagnosis includes neoplasms and other granulomatous disorders such as leprosy, syphilis, and Wegener's granulomatosis [3]. Radiologically, the CT scan and MRI are the recommended examinations.

Lesions varying from localized mucosal thickening to obliterative soft tissue extending from the septum to the lateral wall, opacification of sinuses, and in extreme cases, bone and cartilage involvement may also be present [5]. Le Hir et al. reported that the middle and inferior turbinate are usually affected. There are no clear features of rhinoscleroma on MRI, according to the literature [6].

Biopsies must be performed from the most active sites of this pathology or from the septum and inferior turbinate. Mickulicz cells are not pathognomonic but are characteristic. A chronic inflammatory infiltration of monocytes and lymphocytes has also been described [7]. Furthermore, there are no specific or sensitive tests required to perform the diagnosis. Some authors have reported cellular immunity modifications but with no benefit as regards the diagnosis [5,7,8].

Aggressive therapy must be carried out due to the high recurrence rate of rhinoscleroma [5]. Although early stages can be medically managed with tetracycline or ciprofloxacin, surgery is indicated in the later stages to address the compromised airway and for excision of the granulation or scar tissues [3,4]. Antibiotics are the basis of the treatment. Tetracycline is a historical choice due to its low cost and efficacy (87% of *Klebsiella rhinoscleromatis* are sensitive) [9]. However, this is contraindicated in children or pregnancy, and its recommended dosage is four times daily. Cephalosporin is effective in vitro but pathological relapse may occur when treatment is stopped [10]. Ciprofloxacin seems to be an antibiotic with the best treatment compliance and efficacy [7,9]. The duration of the treatment is uncoded and varies between 6 weeks and 6 months according to the authors [11].

## Conclusion

the clinical outcome of this case demonstrates that surgical treatment alone can be an effective and sufficient approach in managing rhinoscleroma, without the need for prolonged antibiotic therapy, such as ciprofloxacin. This contrasts with the standard practices described in the literature, where antibiotics are typically used for extended periods.

The patient showed excellent recovery, with complete resolution of the mass and relief of nasal obstruction, with no recurrence during postoperative follow-up. This case supports the consideration of surgery as a viable alternative to long-term medical treatment, particularly in pediatric patients or those with contraindications to antibiotics. It offers an opportunity to avoid the potential risks and failures associated with prolonged antibiotic use while providing a second-line surgical option when necessary.

## References

- Hart CA, Rao SK (2000) Editorial: Rhinoscleroma. *J Med Microbiol* 49: 395-396. [Crossref], [Google Scholar], [Indexed]
- Chan TV, Spiegel JH (2007) *Klebsiella rhinoscleromatis* of the membranous nasal septum. *J Laryngol Otol* 121: 998-1002. [Crossref], [Google Scholar], [Indexed]
- Mukara BK, Munyarugamba P, Dazert S, Löhler J (2014) Rhinoscleroma: A case series report and review of the literature. *Eur Arch Otorhinolaryngol* 271: 1851-1856. [Crossref], [Google Scholar], [Indexed]
- Umphress B, Raparia K (2018) Rhinoscleroma. *Arch Pathol Lab Med* 142: 1533-1536. [Crossref], [Google Scholar], [Indexed]
- Ammar ME, Rosen A (2001) Rhinoscleroma mimicking nasal polyposis. *Ann Otol Rhinol Laryngol* 110: 290-292. [Crossref], [Google Scholar], [Indexed]
- Le HP, Marsot-Dupuch K, Bigel P, Elbigoumie TM, Jacquier I, et al. (1996) Rhinoscleroma with orbital extension: CT and MRI. *Neuroradiology* 38: 175-178. [Crossref], [Google Scholar], [Indexed]
- Avery RK, Salman SD, Baker AS (1995) Rhinoscleroma treated with ciprofloxacin: A case report. *Laryngoscope* 105: 854-856. [Crossref], [Google Scholar], [Indexed]
- Berron P, Berron R, Ortiz-Ortiz L (1988) Alterations in the T-lymphocyte subpopulation in patients with rhinoscleroma. *J Clin Microbiol* 26: 1031-1033. [Crossref], [Google Scholar], [Indexed]
- Perkins BA, Hamill RJ, Mushetr DM, O'Hara C (1992) In vitro activities of streptomycin and 11 oral antimicrobial agents against clinical isolates of *Klebsiella rhinoscleromatis*. *Antimicrob Agents Chemother* 36: 1785-1787. [Crossref], [Google Scholar], [Indexed]
- Trautmann M, Held T, Ruhnke M, Schnoy N (1993) A case of rhinoscleroma cured with ciprofloxacin. *Infection* 21: 403-406. [Crossref], [Google Scholar], [Indexed]
- Lassikri O, Benayad J, Lachhab O, El Ayoubi A, Benbouzid MA, et al. (2018) Rhinosclerome du cavum avec expression ganglionnaire cervicale: A propos d'un cas. *Pan African Med J* 30: 116. [Crossref], [Google Scholar], [Indexed]